



Department of Pediatric Cardiac Sciences

Sir Ganga Ram Hospital



DR. NEERAJ AGGARWAL

MD, (Peds), FNH, RGUHS (Pediatric Cardiology)
Consultant Pediatric Cardiologist
E-mail : drneeraj_12@yahoo.co.in
DMC Regn No. : 25394

DR. MRIDUL AGGARWAL

MD, (Peds), FNB, (Pediatric Cardiology) National Board
Consultant Pediatric Cardiologist
E-mail : drmridul@hotmail.com
DMC Regn No. : 35769

DR. JAY RELAN

MD, (Peds), DM (Pediatric Cardiology)
Associate Consultant Pediatric Cardiologist
E-mail : jay.relan@gmail.com
DMC Regn No. : R/8729

Date: 22.07.2022

Mr. Pradeep Singh
Life Care Regeneration Association
New Delhi

Dear Mr. Pradeep

The patient Master Divyansh 6 ½ months old, S/o. Mr. Vikas, R/o Parvaitya Colony, Chacha Chowk, Faridabad Haryana, has been examined by us. He has congenital heart disease which requires Cardiac procedure. The expected cost of procedure is approximately Rs.1, 50,000/- (One Lakh Fifty Thousand only).

This family requires financial assistance for same so kindly help them in all possible way

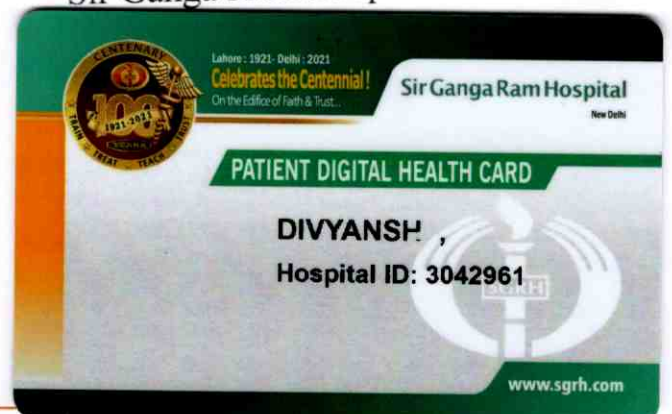Regards,

Neeraj
Dr. Neeraj Aggarwal
Consultant Pediatric Cardiologist
Dept. of Pediatric Cardiac Sciences
Sir Ganga Ram Hospital
New Delhi-110060
DMC No. 25394

Dr. MRIDUL AGGARWAL
MD (Peds), FNB (Pediatric Cardiology)
Consultant, Pediatric Cardiologist
Deptt. of Pediatric Cardiac Sciences
SIR GANGA RAM HOSPITAL
New Delhi-110060
DMC No. 35769

DR. Jay Relan

Consultant Pediatric Cardiologist
Dept. of Pediatric Cardiac Sciences
Sir Ganga Ram Hospital



Sir Ganga Ram Hospital Rajinder Nagar, New Delhi - 110060

OPD Room No. F-57 Timings : 11.00 to 4.00 p.m. Monday to Saturday Ph. : 011-42251757 (For Appointment) 9873818788
For Peripheral OPD Contact : Mr. D. P. Singh : 9358145577, Mr. Anupam Asthana : 9910691524



Department of Pediatric Cardiac Sciences
Sir Ganga Ram Hospital



DR. NEERAJ AGGARWAL

MD, (Peds), FNH, RGHHS (Pediatric Cardiology)
 Consultant Pediatric Cardiologist
 E-mail : drneeraj_12@yahoo.co.in
 DMC Regn No. : 25394

DR. MRIDUL AGGARWAL

MD, (Peds), FNH, (Pediatric Cardiology) National Board
 Consultant Pediatric Cardiologist
 E-mail : drmridul@hotmail.com
 DMC Regn No. : 35769

DR. JAY RELAN

MD, (Peds), DM (Pediatric Cardiology)
 Associate Consultant Pediatric Cardiologist
 E-mail : jay.relan@gmail.com
 DMC Regn No. : R/8729

22/7/22
 DOB: 8/1/22

DIVYANSH
 6 1/2 m / male

PCSPS: 24232/22

* Baby born to 1st gravida mother @ term gest? C/AB. Bwt 2.8kg
 was admitted for 6 days in NICU w/o Neonatal hypoxia

⊛ detected to have a murmur @ 2 weeks of age.
 Diagnosed to have CHD.

⊛ Poor wt gain. wt 3.5kg, 1 month back.

O/E Awake, alert

CVS ESM 2/6 @ WSB.

Echoc done: Severe valvular PS, RVH.
 Smn OS-ASD.

Plan

- Pulmonary valve balloon dilatation.
- Needs NGO help.


Jay

Dr. NEERAJ AGGARWAL
 MD (Peds), FNH, RGHHS (Ped. Card).
 Director and Consultant, Pediatric Cardiology
 Deptt. of Pediatric Cardiac Sciences
 SIR GANGA RAM HOSPITAL
 New Delhi-110060
 DMC No. 25394

Sir Ganga Ram Hospital Rajinder Nagar, New Delhi - 110060



H-2008-0017
June 16, 2020 - June 15, 2023
Since June 16, 2008



Sir Ganga Ram Hospital

Department of Pediatric Cardiac Sciences

NAME : DIVYANSH

SEX : MALE

DATE : 22.07.2022

AGE : 6 ½ MONTHS

PCS ID NO. : 24232/22

REF. BY : DR. KAPIL

Pediatric Echo Report

Cardiac Position

Abdominal Situs Solitus

Levocardia

Cardiac Segments

Atrial Situs Solitus

D-loop ventricle

AV Concordance

Two Patent AV Valves

VA concordance

Normally related great Arteries

Veins & Atria

Normal Systemic Venous Drainage

Normal pulmonary Venous Drainage

Interatrial septum, **Small 3mm ASD (Left to right shunt).**

Normal RA Size

Normal LA Size

Atrioventricular Canal

Normal Mitral valve

Normal Tricuspid valve



H-2008-0017
June 16, 2020 - June 15, 2023
Since June 16, 2008



Sir Ganga Ram Hospital

Ventricles

Normal left ventricle

Right ventricle, **Hypertrophy.**

Intact Interventricular septum

Conotruncus

Normal Left ventricular outflow tract and aortic valve.

Normal Right Ventricular outflow tract, **Doming pulmonary valve peak gradient 65mm HG.**

Great Arteries

Normal Ascending Aorta, arch and descending aorta

No PDA/Coarctation

Confluent branch pulmonary arteries.

Function

Normal RV Function

Normal LV Function

(LVEF=60%)

Effusion

No pericardial effusion

Coronaries

Normal Coronary arteries

INTERPRETATION

- **SEVERE VALVAR PS.**
- **RVH.**
- **GOOD BIVENTRICLE FUNCTION.**

Jay
For Dr. Neeraj Aggarwal

DR. NEERAJ AGGARWAL
(peds), FNH, RGUHS (Pediatric Cardiology)
CONSULTANT, PEDIATRIC CARDIOLOGIST
Sir Ganga Ram Hospital, New Delhi

Dr. MRIDUL AGARWAL
MD (peds), FNB, (Pediatric Cardiology)
CONSULTANT, PEDIATRIC CARDIOLOGIST
Sir Ganga Ram Hospital, New Delhi

Dr. Jay Relan
MD (Peds), DM (Pediatric Cardiology)
CONSULTANT, PEDIATRIC CARDIOLOGIST
Sir Ganga Ram Hospital, New Del



भारतीय विशिष्ट पहचान प्राधिकरण
भारत सरकार
Unique Identification Authority of India
Government of India

नामांकन क्रम/Enrolment No.: 1028/12018/16640

Download Date: 23/02/2017

To
विकास
Vikas
S/O: Chhitar Mal
House-239
Ward-6, Gali-3
Sanjay Enclave
Nangla Road
Faridabad Sector 22
Faridabad Faridabad Sector 22
Haryana - 121005

Generation Date: 09/10/2012

Signature Not Verified
Digitally signed by
UNIQUE IDENTIFICATION
AUTHORITY OF INDIA 02
DN: cn=UNIQUE IDENTIFICATION
AUTHORITY OF INDIA 02, o=



आपका आधार क्रमांक / Your Aadhaar No. :

8770


मेरा आधार, मेरी पहचान



भारत सरकार
Government of India



विकास
Vikas
जन्म तिथि/ DOB: 17/01/1994
पुरुष / MALE



8770

मेरा आधार, मेरी पहचान



Government of India

सूचन

- आधार पहचान का प्र
- पहचान का प्रमाण औ
- यह एक इलेक्ट्रॉनिक

INFI

- Aadhaar is a j
- To establish id
- This is electron

- आधार देश भर में
- आधार भविष्य में स
- का लाभ उठाने में स
- Aadhaar is valid
- Aadhaar will be
- and Non-Govern



भारत
Uni

पता:
S/O: छितर मल, हाउस-239
6, गली-3, नंगला मार्ग, संजय
इनक्लेव, फरीदाबाद सेक्टर 22
फरीदाबाद,
हरयाणा - 121005



1947